ERNST VON BERGMANN KLINIKUM POTSDAM

HMU Health and Medical University

Interventionelle Therapie der KHK mit medikamentenbeschichteten Ballonkathetern

# Drug-Coated Balloon

Klaus Bonaventura | 13. November 2025 | Luzern

ERNST VON BERGMANN KLINIKUM POTSDAM

Werderaner Baumblütenfest

## Drug-coated Balloon

ERNST VON BERGMANN KLINIKUM POTSDAM

Frau, 54 Jahre,
Vorderwand-STEMI,
kardiogener Schock,
PCI LAD

De-novo Koronarstenosen

## Frau, 54 Jahre

Vorderwand-STEMI, kardiogener Schock, PCI LAD

ERNST VON BERGMANN KLINIKUM POTSDAM

RCA

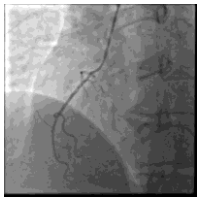

LAD

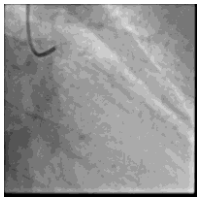

## Frau, 54 Jahre
Vorderwand-STEMI, kardiogener Schock, PCI LAD

LAD

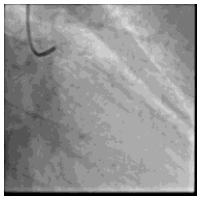

## Frau, 54 Jahre
Vorderwand-STEMI, kardiogener Schock, PCI LAD

LAD ostium

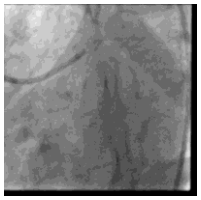

Impella CP

Single-access

## Frau, 54 Jahre
Vorderwand-STEMI, kardiogener Schock, PCI LAD

LAD

nach Einbringen der Impella CP

LAD

Führungsdrähte in LAD und CX

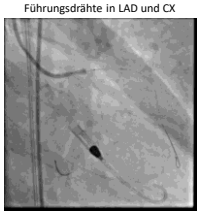

## Frau, 54 Jahre
Vorderwand-STEMI, kardiogener Schock, PCI LAD

Läsionspräparation der LAD

Scoring Balloon NSE alpha® 3,5/13 mm

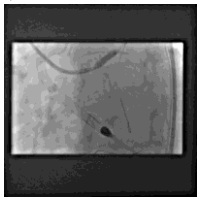

## Frau, 54 Jahre
Vorderwand-STEMI, kardiogener Schock, PCI LAD

Ergebnis nach Läsionspräparation der LAD

Scoring Balloon NSE alpha® 3,5/13 mm

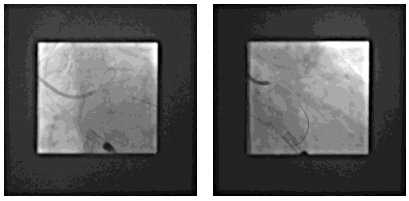

## Frau, 54 Jahre
Vorderwand-STEMI, kardiogener Schock, PCI LAD

DCB im Ostium der LAD

SeQuent® Please NEO 3,5/20 mm

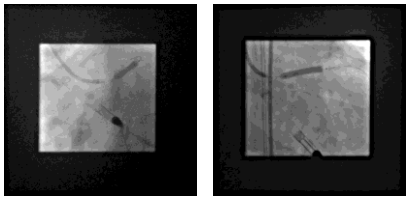

## Frau, 54 Jahre
Vorderwand-STEMI, kardiogener Schock, PCI LAD

Ergebnis nach DCB im Ostium der LAD

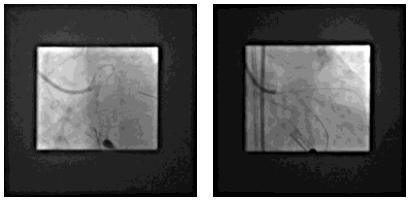

## Frau, 54 Jahre
Vorderwand-STEMI, kardiogener Schock, PCI LAD

Ergebnis nach DCB im Ostium der LAD

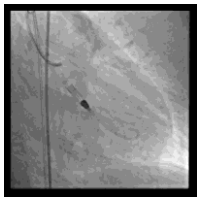

## Frau, 54 Jahre
Vorderwand-STEMI, kardiogener Schock, PCI LAD

Langzeitergebnis der LAD nach 5 Monaten

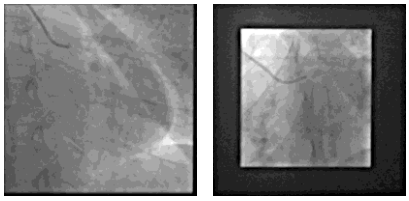

## Frau, 54 Jahre
Vorderwand-STEMI, kardiogener Schock, PCI LAD

Langzeitergebnis der LAD nach 5 Monaten

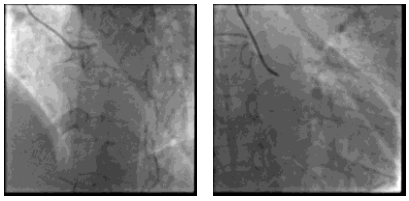

Wir erinnern uns …

Andreas Gruentzig 1939 - 1985

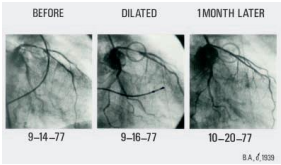

Perkutane transluminale Koronarangioplastie (PTCA)

17

Schwere Intimadissektion nach Ballonangioplastie

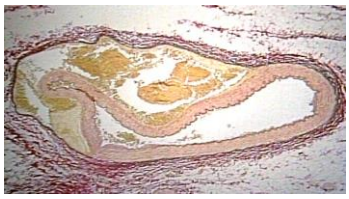

Perfusion Balloon

1994: Stentimplantation bei 5% der Patienten

The New England
Journal of Medicine

©Copyright, 1994, by the Massachusetts Medical Society

Volume 331 AUGUST 25, 1994 Number 8

**A COMPARISON OF BALLOON-EXPANDABLE-STENT IMPLANTATION WITH BALLOON ANGIOPLASTY IN PATIENTS WITH CORONARY ARTERY DISEASE**

Patrick W. Serruys, M.D., Peter de Jaegere, M.D., Ferdinand Kiemeneij, M.D., Carlos Macaya, M.D., Wolfgang Rutsch, M.D., Guy Heyndrickx, M.D., Håkan Emanuelsson, M.D., Jean Marco, M.D., Victor Legrand, M.D., Pierre Materne, M.D., Jorge Belardi, M.D., Ulrich Sigwart, M.D., Antonio Colombo, M.D., Jean Jacques Goy, M.D., Paul van den Heuvel, M.D., Jean Delcan, M.D., and Marie-Angèle Morel, M.Sc., for the Benestent Study Group*

Of the 257 remaining patients randomly assigned to balloon angioplasty, 13 (5.1 percent) received stents for the following reasons: acute vessel closure in 1, flow-limiting dissection in 11, and a suboptimal angiographic result in 1.

Serruys PW et al. N Engl J Med. 1994 Aug 25;331(8):489-95.

Bare-metal stent (BMS)



Stentimplantation



Erste Indikation der Implantation von BMS

Bail-out Indikation:

*"to bail somebody out"*
*to help someone in a difficult problem*

Erste Indikation der Implantation von BMS

## Indikation zur BMS-Implantation wechselte

von der Bail-out Indikation zur Behandlung der KHK

## Restenose nach BMS-Implantation

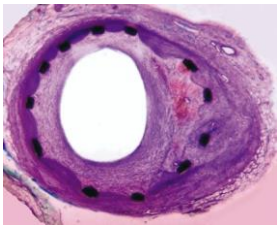

## Drug-eluting Stent (DES)

Medikamentenbeschichtung reduziert Intimaproliferation im Stent

Ohne
Medikamentenbeschichtung

Mit
Medikamentenbeschichtung

## Drug-eluting Stent (DES)

Medikamentenbeschichtung reduziert Intimaproliferation im Stent

## Drug-eluting Stent (DES)

Paclitaxel & Sirolimus reduzieren Intimaproliferation im Stent

## … und weil DES > BMS

wurde die **DES-Implantation die Therapie der ersten Wahl**
bei der interventionellen Therapie der KHK

Drug-eluting Stent

## "Full metal jacket"

Am Heart J. 2005 Nov;150(5):994-9.

**"Full metal jacket" (stented length > or =64 mm) using drug-eluting stents for de novo coronary artery lesions.**

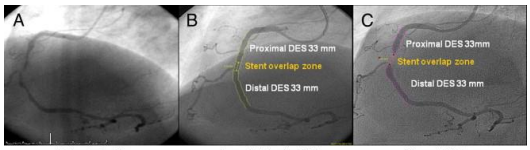


Untreated lesion | Immediately after PCI | 24 month follow up

Drug-eluting Stent

## 56-jähriger Patient mit 67 Stents in 28 Interventionen

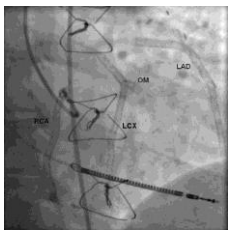


Khouzam RN, Dahiya R, and Schwartz R. J Am Coll Cardiol. 2010;56:1605

Drug-eluting Stent

6 Monate duale
Thrombozytenaggregationshemmung

Heterogenität der neointimalen Heilung nach
Drug-eluting Stent




Joner M et al. J Am Coll Cardiol, 2008; 52:333-342.

DES Metaanalyse
5-Jahres Outcome nach DES-Implantation

Stent-bezogene Ereignisrate: 2-3% pro Jahr
Target lesion failure

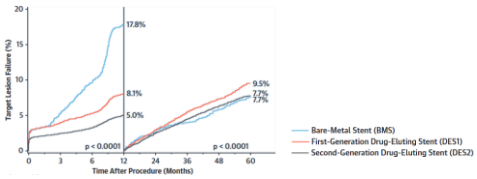


Madhavan MV et al. J Am Coll Cardiol. 2020 Feb 18;75(6):590-604.

Drug-eluting Stent

Lebenslanges Risiko einer Stentthrombose
(0,5-1% pro Jahr)

Definition des interventionellen Erfolges

- **MACE** (Major Adverse Clinical Events)
  Tod, Myokardinfarkt, Revaskularisierung (Re-PCI, CABG), Schlaganfall
- **Erneute Revaskularisierung**
  **TLR:** Target Lesion Revascularization
- **Angiographisches Ergebnis**
  **LLL:** Late Lumen Loss

Drug-coated Balloon

Drug-coated Balloon

≙ Drug-eluting Balloon (DEB)

Drug-coated Balloon (DCB)

≙ ~~Drug-eluting Balloon (DEB)~~

## Drug-coated Balloon

## Drug coating

Coating

## Drug-coated Balloon

- 100% Abdeckung der Läsion mit Medikament
- Sofortige Medikamentenabgabe
- Rasche Endothelialisierung
- Kein Polymer
- Erhält die originale Gefäßanatomie

## Drug-eluting Stent

- 16% Abdeckung der Läsion mit Medikament
- Stent
- Langsame Endothelialisierung
- Polymer

## Drug-coated Balloon

SeQuent® please NEO

Agent™

DIOR®

Prevail™

Pantera® Lux

SELUTION SLR™

MagicTouch™ SCB

SeQuent® SCB

## Kein Klasseneffekt bei Drug-coated Balloon

## Drug-coated balloon treatment recommendations

International consensus group

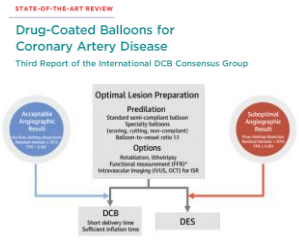


Jeger RV et al. JACC Cardiovasc Interv. 2020 Jun 22;13(12):1391-1402.

200+

30.000+

35+

## Drug-coated Balloon

In-stent Restenose

De-novo coronary lesions

InStent-Restenose

## Drug-coated Balloon



THE NEW ENGLAND JOURNAL of MEDICINE

ORIGINAL ARTICLE

Treatment of Coronary In-Stent Restenosis with a Paclitaxel-Coated Balloon Catheter

Bruno Scheller, M.D., Christoph Hehrlein, M.D., Wolfgang Bocksch, M.D., Wolfgang Rutsch, M.D., Dariush Haghi, M.D., Ulrich Dietz, M.D., Michael Böhm, M.D., and Ulrich Speck, Ph.D.

ABSTRACT

BACKGROUND

Treatment of coronary in-stent restenosis is hampered by a high incidence of recurrence in-stent restenosis. We assessed the efficacy and safety of a paclitaxel-coated balloon in this setting.

METHODS

We enrolled 51 patients with in-stent restenosis in a randomized, double-blind, multicenter trial to compare the effects of a balloon catheter coated with paclitaxel (3 µg per square millimeter of balloon surface area) with those of an uncoated balloon catheter in coronary angioplasty. The primary end point was late luminal loss as seen on angiography. Secondary end points included the rates of restenosis (a binary variable) and major adverse cardiac events.

Scheller B et al. N Engl J Med 2006; 355:2113-2124

2018

## ESC Guidelines on myocardial revascularization



ESC European Society of Cardiology

European Heart Journal (2018) 00, 1–96 doi:10.1093/eurheartj/ehy394

ESC/EACTS GUIDELINES

2018 ESC/EACTS Guidelines on myocardial revascularization

The Task Force on myocardial revascularization of the European Society of Cardiology (ESC) and European Association for Cardio-Thoracic Surgery (EACTS)

| Restenosis | | |
|---|---|---|
| DES are recommended for the treatment of in-stent restenosis of BMS or DES.[373,375,378,379] | I | A |
| Drug-coated balloons are recommended for the treatment of in-stent restenosis of BMS or DES.[373,375,378,379] | I | A |
| In patients with recurrent episodes of diffuse in-stent restenosis, CABG should be considered by the Heart Team over a new PCI attempt. | IIa | C |
| IVUS and/or OCT should be considered to detect stent-related mechanical problems leading to restenosis. | IIa | C |

European Heart Journal doi:10.1093/eurheartj/ehy394.

## Drug-coated Balloon

Mann, 78 Jahre,
stabile KHK,
positiver Belastungstest,
PCI LAD-ISR

In-stent Restenose

## Mann, 78 Jahre
Stabile KHK, positiver Belastungstest, PCI LAD-ISR

LAD In-stent Restenose

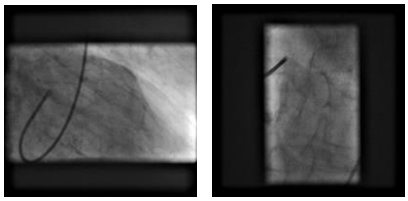

## Mann, 78 Jahre
Stabile KHK, positiver Belastungstest, PCI LAD-ISR

Läsionspräparation der LAD

Emerge® 2,5/20 mm

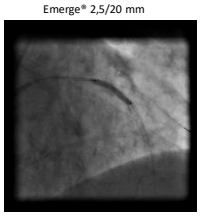

DCB in LAD

DCB SeQuent® Please NEO 2,5/30 mm

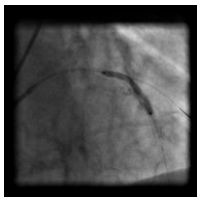

## Mann, 78 Jahre
Stabile KHK, positiver Belastungstest, PCI LAD-ISR

Ergebnis nach DCB der LAD

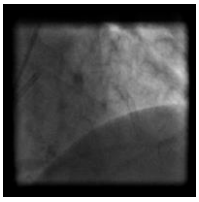

## Mann, 78 Jahre
Stabile KHK, positiver Belastungstest, PCI LAD-ISR

Langzeitergebnis der LAD nach 4 Monaten

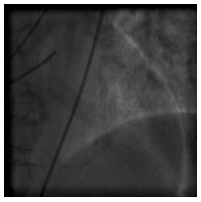

Drug-coated Balloon

In-stent restenosis

De-novo Koronarstenosen

Drug-coated Balloon

Frau, 67 Jahre,
stabile KHK,
positiver Belastungstest,
PCI OM1CX

De-novo Koronarstenosen

Frau, 67 Jahre
Stabile KHK, positiver Belastungstest, PCI M1CX

M1CX

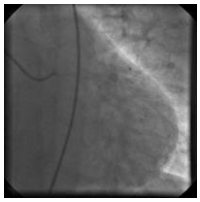

M1CX nach Läsionspräparation
Emerge® 2,5/15 mm

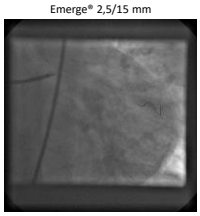

Frau, 67 Jahre
Stabile KHK, positiver Belastungstest, PCI M1CX

DCB in M1CX
Sequent® Please neo 2.5/20 mm

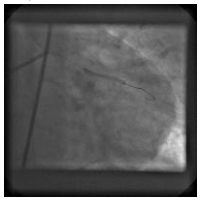

DCB sollte den vordilatierten Bereich proximal und distal um mehr als 2-3 mm abdecken.

## Frau, 67 Jahre
Stabile KHK, positiver Belastungstest, PCI M1CX

DCB in M1CX

SeQuent® Please NEO 2,5/20 mm

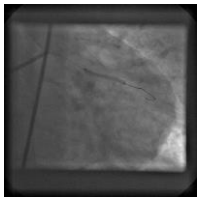

Ergebnis nach DCB

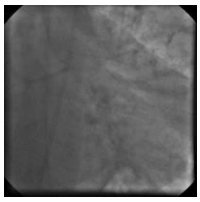

## Frau, 67 Jahre
Stabile KHK, positiver Belastungstest, PCI M1CX

Langzeitergebnis des M1CX nach 4 Monaten

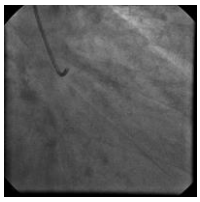

## Frau, 67 Jahre
Stabile KHK, positiver Belastungstest, PCI M1CX

Initiales Ergebnis

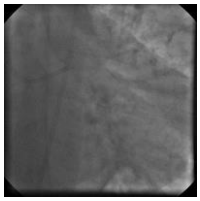

Langzeitergebnis nach 4 Monaten

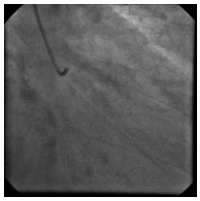

Positives Gefäßremodeling
Lumen enlargement (LLE)

LLE in 2 von 3 DCB-Prozeduren

Therapie von De-novo Koronarstenosen mit DCB
Chinese institute

Vergleich Late lumen loss (LLL) bei 91 Stenosen im Follow-up
(10,7 ± 5,7 Monate)

| | All lesions | LVD group (≥ 2.8 mm) ($n = 45$) | SVD group (< 2.8 m) ($n = 46$) | *P* value |
|---|---|---|---|---|
| LLL (mm) | − 0.17 ± 0.53 | − 0.17 ± 0.62 | − 0.17 ± 0.43 | 0.993 |

Yu X et al. Clinical Research in Cardiology (2019) 108:234–243.

Positives Gefäßremodeling nach DCB

- Auswirkungen von Paclitaxel auf die Gefäßwand
- Hemmung der Proliferation der glatten Muskelzellen
- Auswirkungen nicht nur auf das neointimale Wachstum, sondern auch auf die Ausdünnung der Media
- Plaque-Regression oder Gefäßheilung

Vasomotion

## Drug-coated Balloon

De-novo Koronarstenosen

Läsions-präparation

## Möglichkeiten der Läsionspräparation

- Semi-compliant Balloon
- Non-compliant Balloon
- OPN/Super high pressure PTCA Balloon
- Scoring Balloon
- Cutting Balloon
- Rotablation
- Koronare intravaskuläre Lithotripsie (Shockwave®)

## PASSWORD observational study

Systematic scoring balloon lesion preparation for DCB in clinical routine

481 Patienten (496 Läsionen), prospektive, multizentrische, einarmige All-Comers-Studie bei Patienten mit De-novo Stenosen und In-stent Restenosen

**Scoring Balloon** (Lacrosse NSE®) + **DCB** (Sequent Please Neo®)

Bonaventura K et al. Adv Ther. 2020 May;37(5):2210-2223.

## Scoring balloon
## NSE Alpha™ scoring Balloon

3 rutschfeste Scoring-Elemente auf Ballonoberfläche

## PASSWORD observational study
Systematic scoring balloon lesion preparation for DCB in clinical routine

Klinische Ergebnisse für De-novo Stenosen nach 9,4 Monaten

| | De-novo Stenosen |
|---|---|
| Target lesion revascularization | 0,8 % |
| Myokardinfarkt | 0 % |

Bonaventura K et al. Adv Ther. 2020 May;37(5):2210-2223.

## Drug-coated Balloon

Mann, 64 Jahre,
NSTEMI, Troponin +,
PCI M2CX und CX

Akutes Koronarsyndrom

## Mann, 64 Jahre
NSTEMI, PCI M2CX und CX

CX/M2CX

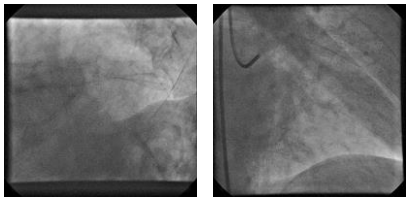

## Mann, 64 Jahre
NSTEMI, PCI M2CX und CX

Läsionspräparation M2CX
Emerge® 2,0/15 mm

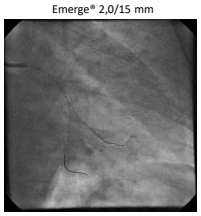

Ergebnis nach Läsionspräparation

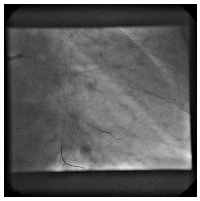

Mann, 64 Jahre
NSTEMI, PCI M2CX und CX

DCB in M2CX

SeQuent® Please NEO 2,0/20 mm

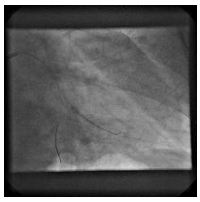

Ergebnis nach DCB in M2CX

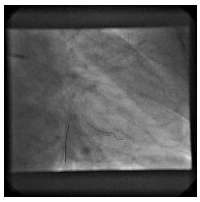

Mann, 64 Jahre
NSTEMI, PCI M2CX und CX

Läsionspräparation CX

Emerge® 3,0/15 mm

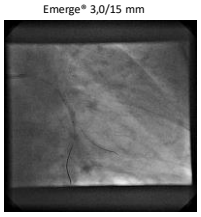

Ergebnis nach Läsionspräparation

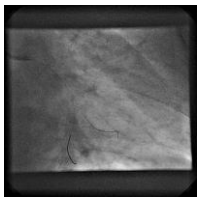

Mann, 64 Jahre
NSTEMI, PCI M2CX und CX

DCB in CX

SeQuent® Please NEO 3,0/20 mm

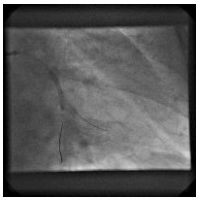

Mann, 64 Jahre
NSTEMI, PCI M2CX und CX

Ergebnis nach DCB in M2CX und CX

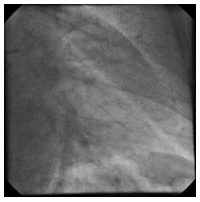

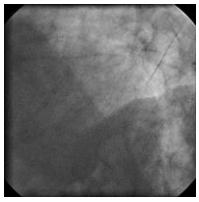

Mann, 64 Jahre
NSTEMI, PCI M2CX und CX

Ergebnis nach DCB in M2CX und CX

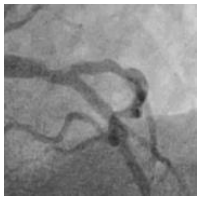

- Reststenose von 40-50%
- Type C Dissection
- TIMI III flow
- Kein Kontrastmitteldepot in Gefäßwand

Mann, 64 Jahre
NSTEMI, PCI M2CX und CX

Langzeitergebnis von M2CX und CX nach 9 Monaten

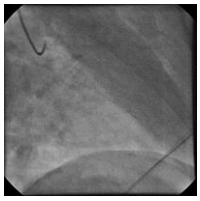

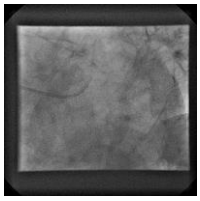

It´s all about
lesion preparation

Welche Dissektionen sind unkompliziert oder benigne?
- in 2025

A

B

C

TIMI III flow

Kann ich im Dienst ruhig schlafen?

BASKET SMALL 2
Drug-coated balloons for small coronary artery disease

Thrombotische Ereignisse

**0%**
Thrombotic Events after DCB-Only[1]

1 Jeger RV et al. Lancet 2018. http://dx.doi.org/10.1016/S0140-6736(18)31719-7.

Risiko einer Thrombose in De-novo Stenosen nach DCB < nach DES

Bonaventura K. Eurointervention 2011;7:K125-128

Chronisches Koronarsyndrom
Drug-coated Balloon

4 Wochen duale Thrombozytenaggregationshemmung

Drug-coated Balloon

De-novo Koronarstenosen

Schmalkalibrige Gefäße

## BASKET SMALL 2
Drug-coated balloons for small coronary artery disease

### Primärer Endpunkt
Outcome nach 12 Monaten: Kardialer Tod, nicht-tödlicher MI, Revasularisation

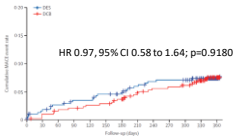


→ DCB ist dem DES nicht unterlegen

Jeger RV et al. Lancet 2018. http://dx.doi.org/10.1016/S0140-6736(18)31719-7.

## Drug-coated balloon

De-novo Koronarstenosen

Großkalibrige Gefäße

## DCB versus DES for large vessel coronary artery disease
a systematic review and meta-analysis of 13 studies involving 2,888 patients

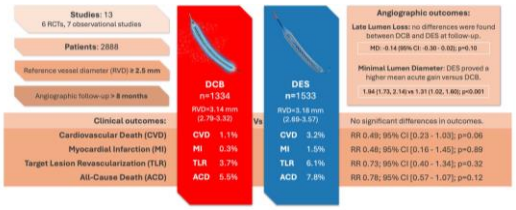


Caminiti R et al. Clin Res Cardiol. 2024 Jul 3.

## Paclitaxel drug-coated balloon
for the treatment of de novo small-vessel and restenotic coronary artery lesions (PREVAIL Study)

50 Patienten (53 Stenosen), prospektive, multizentrische, single-arm Studie bei Patienten mit De-novo Stenosen oder erster ISR

**Läsionspräparation** + **DCB** (Prevail®, Medtronic)

Latib A et al. J Invasive Cardiol. 2021 Nov;33(11):E863-E869.

## Paclitaxel drug-coated balloon

for the treatment of de novo small-vessel and restenotic coronary artery lesions (PREVAIL Study)

### Late lumen loss

nach 6 Monaten

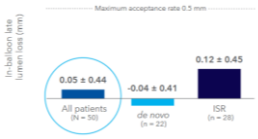


### MACE

Tod, TV-MI, oder Stent-/Läsion-Thrombose

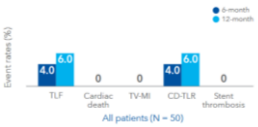


Latib A, et al. PREVAIL Study 12-month results. Results presented at PCR 2020.

## Drug-coated Balloon

Lazar FL et al. AsiaIntervention 2024;10:15-25 | 10.4244/AII-D-23-00010

## Drug-coated balloon

De-novo Koronarstenosen

Paclitaxel vs. Sirolimus

Vergleich von

## Sirolimus- vs. Paclitaxel-coated Balloon

Sirolimus bietet potentielle Vorteile gegenüber Paclitaxel

| Eigenschaften | Sirolimus (oder Analoga) | Paclitaxel |
|---|---|---|
| Gewebeabsorption | Langsam | Schnell |
| Geweberetention | Kurz | Lang |

## Drug-coated Balloon
bei koronarer Herzerkrankung

Schneller, homogener und effektiver Medikamententransfer in Gefäßwand

## Treatment of coronary de novo lesions by a Sirolimus- or Paclitaxel-coated balloon

70 Patienten mit koronaren De-novo Läsionen, randomisierte, multizentrische Studie in Malaysia

**PCB** Sequent Please neo 3 µg/mm² vs. **SCB** SeQuent SCB 4 µg/mm²

Ahmed WAW et al. J Am Coll Cardiol Intv 2022;15:770–779.

## Treatment of coronary de novo lesions by a Sirolimus- or Paclitaxel-coated balloon

Angiographisches Late lumen loss nach 6 Monaten

| | Paclitaxel-coated DCB | Sirolimus-coated DCB | Threshold for Noninferiority |
|---|---|---|---|
| In-lesion LLL, mm | 0.05 | 0.11 | <0.35 |
| In-segment LLL, mm | 0.01 | 0.10 | <0.35 |

Ahmed WAW et al. J Am Coll Cardiol Intv 2022;15:770–779.

## TRANSFORM I
Comparing Sirolimus-coated balloon with Paclitaxel-coated balloon in de-novo small vessels

121 Patienten (129 Läsionen) mit Erkrankungen der kleinen Gefäße; prospektive, randomisierte, multizentrische, offene Nicht-Unterlegenheitsstudie

**60 Patienten** behandelt mit **Sequent Please PCB** (B. Braun) vs. **61 Patienten** behandelt mit **Magic Touch SCB** (Concept Medical, India)

Ninomiya K et al. J Am Coll Cardiol Intv. 2023.

## TRANSFORM I

Comparing Sirolimus-coated balloon with Paclitaxel-coated balloon in de-novo small vessels

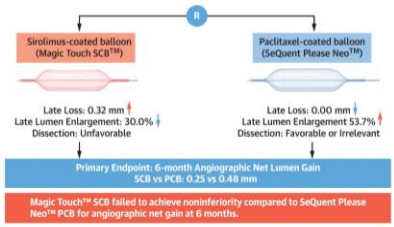


Ninomiya K et al. J Am Coll Cardiol Intv. 2023.

## SELUTION SLR balloon

with sustained limus release

## SELUTION DeNovo trial

comparing a strategy of PCI with a sirolimus-eluting balloon and provisional stenting versus systematic DES implantation to treat de novo coronary lesions

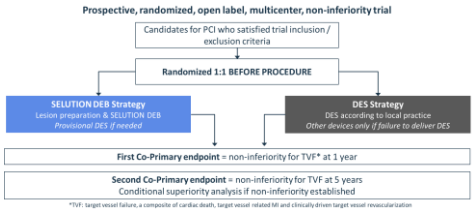


Spaulding C et al. Am Heart J. 2023 Apr;258:77-84.

## SELUTION DeNovo trial

comparing a strategy of PCI with a sirolimus-eluting balloon and provisional stenting versus systematic DES implantation to treat de novo coronary lesions

### Primary Endpoint Results: TVF at 1-Year

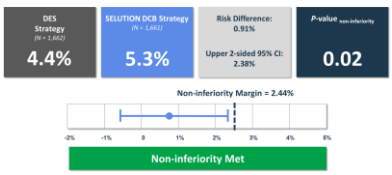


Spaulding C et al. TCT 2025.

Wir behandeln Koronarstenosen
& wollen die Restenose verhindern …

Single approach

DES DCB

Hybrid approach

DES & DCB

Ergebnis der Läsionspräparation

DES oder DCB

## Clinical impact of DCB-based PCI in patients
with multivessel coronary artery disease

254 Patienten mit Mehrgefäßerkrankungen, die mit DCBs oder in Kombination mit DES behandelt wurden

- verglichen mit 254 Patienten mit Propensity-Matching, die mit DES der zweiten Generation behandelt wurden

**Hybrid approach DCB** Sequent Please neo **oder DCB + DES** vs. **DES only**

Shin ES et al. J Am Coll Cardiol Intv 2023.

## Clinical impact of DCB-based PCI in patients
with multivessel coronary artery disease

Klinische und verfahrenstechnische Merkmale

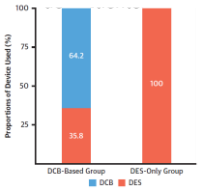


Shin ES et al. J Am Coll Cardiol Intv 2023.

## Clinical impact of DCB-based PCI in patients
with multivessel coronary artery disease

Klinische Ergebnisse bei der 2-Jahres-Nachbeobachtung

MACE

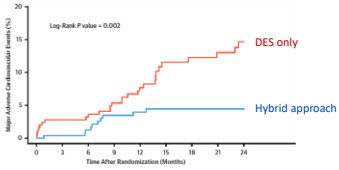


Shin ES et al. J Am Coll Cardiol Intv 2023.

Drei letzte Fallbeispiele …

Frau, 63 Jahre
NSTEMI, PCI Bifurkationsstenose LAD/D1

Drug-coated Balloon

Frau, 63 Jahre,
NSTEMI,
PCI LAD/D1

De-novo
Koronarstenosen

Frau, 63 Jahre
NSTEMI, PCI Bifurkationsstenose LAD/D1

RCA

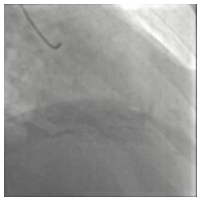

LAD Medina 1/1/1

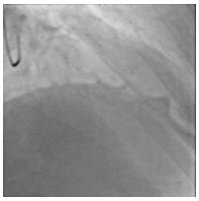

Frau, 63 Jahre
NSTEMI, PCI Bifurkationsstenose LAD/D1

Läsionspräparation LAD/D1

Emerge® 3,5/15 mm, Emerge® 2,75/15 mm

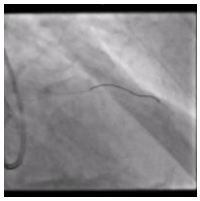

Ergebnis nach Läsionspräparation

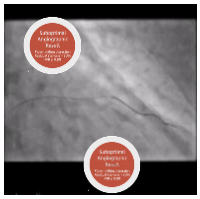

Double crush stenting

## Frau, 63 Jahre
NSTEMI, PCI Bifurkationsstenose LAD/D1

2 DES in LAD und D1

Coroflex® ISAR NEO 3,5/19 mm + 2,75/19 mm

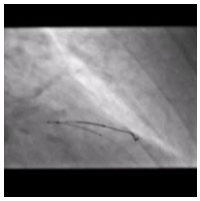

Postdilatation Hochdruck-Balloon

3,5/15 mm

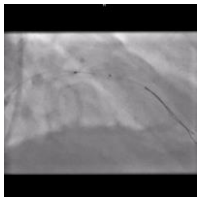

## Frau, 63 Jahre
NSTEMI, PCI Bifurkationsstenose LAD/D1

Ergebnis nach 2 DES in LAD/D1

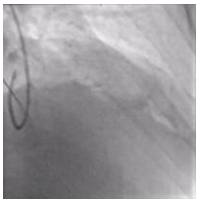

## Frau, 63 Jahre
NSTEMI, PCI Bifurkationsstenose LAD/D1

Langzeitergebnis nach 2 DES nach 4 Monaten

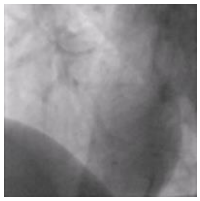

## Frau, 84 Jahre
Instabile Angina pectoris, PCI Bifurkationsstenose LAD/D1

## Drug-coated Balloon

Frau, 84 Jahre,
instabile Angina pectoris,
PCI LAD/D1

De-novo Koronarstenosen

## Frau, 84 Jahre
Instabile Angina pectoris, PCI Bifurkationsstenose LAD/D1

LAD Medina 1/1/1

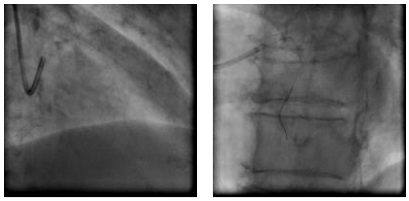

## Frau, 84 Jahre
Instabile Angina pectoris, PCI Bifurkationsstenose LAD/D1

Läsionspräparation D1
Scoring NSE alpha® 2,5/13 mm

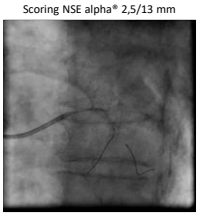

Läsionspräparation LAD
Scoring NSE alpha® 3,5/13 mm

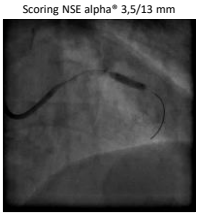

## Frau, 84 Jahre
Instabile Angina pectoris, PCI Bifurkationsstenose LAD/D1

Ergebnis nach Läsionspräparation von LAD und D1

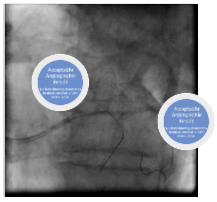

## Frau, 84 Jahre
Instabile Angina pectoris, PCI Bifurkationsstenose LAD/D1

DCB in D1

SeQuent® Please NEO 2,5/20 mm

DCB in LAD

SeQuent® Please NEO 3,5/20 mm

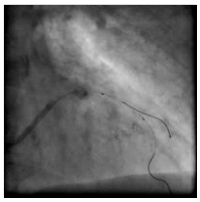

## Frau, 84 Jahre
Instabile Angina pectoris, PCI Bifurkationsstenose LAD/D1

Ergebnis nach DCB in LAD/D1

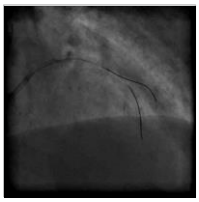

## Frau, 84 Jahre
Instabile Angina pectoris, PCI Bifurkationsstenose LAD/D1

Langzeitergebnis nach 2 DCB in LAD/D1 nach 3 Monaten

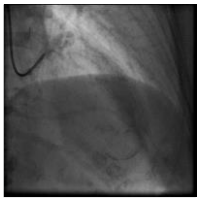

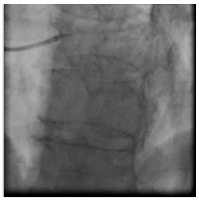

## Frau, 55 Jahre
Stable Angina pectoris, positive Belastungstest, PCI CX

## Drug-coated Balloon

Frau, 55 Jahre,
stable Angina pectoris, positiver Belastungstest, PCI CX

De-novo Koronarstenosen

## Frau, 55 Jahre
Stable Angina pectoris, positive Belastungstest, PCI CX

CX

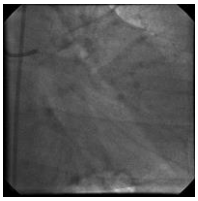

## Frau, 55 Jahre
Stable Angina pectoris, positive Belastungstest, PCI CX

Läsionspräparation CX

Emerge® 3,5/15 mm, Emerge® 2,5/15 mm



Ergebnis nach Läsionspräparation



## Frau, 55 Jahre
Stable Angina pectoris, positive Belastungstest, PCI CX

2 DCB distal & medial

SeQuent® Please NEO 2,5/20 mm



1 DES proximal

Coroflex® ISAR NEO 3,5/16 mm

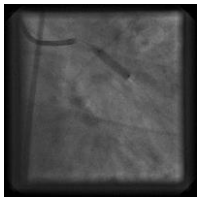

## Frau, 55 Jahre
Stable Angina pectoris, positive Belastungstest, PCI CX

Ergebnis nach DES proximal und 2 DCB medial & distal



## Frau, 55 Jahre
Stable Angina pectoris, positive Belastungstest, PCI CX

Langzeitergebnis nach 4 Monaten

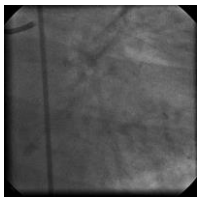

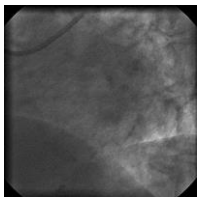

## Hybrid approach
in der interventionellen Therapie von koronaren De-novo Stenosen

Hybrid approach

## Hybrid approach
in der interventionellen Therapie von koronaren De-novo Stenosen

Basierend auf dem Ergebnis der Läsionsvorbereitung bedeutet der Hybrid approach von Stent & DCB, alle Optionen in Betracht zu ziehen

- “Stent only” oder
- “DCB only” oder
- “Stent & DCB” in einem Gefäß oder in einer Stenose

Drug-coated Balloon
## Zusammenfassung

- DCB zeigt eine nachgewiesene Wirksamkeit und Sicherheit bei De-novo Koronarstenosen.
- Die optimale Läsionspräparation ist ein wichtiger Schritt des Behandlungsalgorithmus.
- Der Hybrid Approach von DCB und Stenting nutzt alle zeitgemäßen Möglichkeiten, um das beste interventionelle und klinische Ergebnis zu erzielen.

## Was ist unsere Erfahrung?

## Etwa 1.100 PCI pro Jahr

Etwa 1.100 PCI pro Jahr

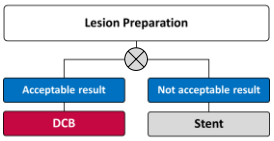


Etwa 1.100 PCI pro Jahr

**ca. 600 DCB pro Jahr**

Etwa 1.100 PCI pro Jahr

**ca. 400 Scoring Balloons pro Jahr**

Etwa 1.100 PCI pro Jahr

**> 50% der PCI: DCB only**

Etwa 1.100 PCI pro Jahr

> 50% aller PCI: DCB only

**TLR @ 12 Monate 1,8%, Thrombosen <0,05%**

Vielen Dank für Ihre Aufmerksamkeit